

## CASE REPORT

# Impacted Lower Third Molar Fused with a Supernumerary Tooth —Diagnosis and Treatment Planning Using Cone-Beam Computed Tomography

Osny Ferreira-Junior<sup>1\*</sup>, Luciana Dorigatti de Ávila<sup>1</sup>, Marcelo Bonifácio da Silva Sampieri<sup>1</sup>, Eduardo Dias-Ribeiro<sup>1</sup>, Wei-liang Chen<sup>2</sup>, Song Fan<sup>2\*</sup>

<sup>1</sup>Department of Stomatology, Dental School of Bauru, University of São Paulo, Bauru, São Paulo, Brazil

<sup>2</sup>Department of Stomatology, the Second Affiliated Hospital, Sun Yat-Sen University, Guangzhou, China

## Abstract

**Osny Ferreira-Junior, Luciana Dorigatti de Ávila, Marcelo Bonifácio da Silva Sampieri, Eduardo Dias-Ribeiro, Wei-liang Chen, Song Fan.** Impacted Lower Third Molar Fused with a Supernumerary Tooth—Diagnosis and Treatment Planning Using Cone-Beam Computed Tomography. *International Journal of Oral Science*, 1(4): 224–228, 2009

This paper reported a case of fusion between an impacted third molar and a supernumerary tooth, in which a surgical intervention was carried out, with the objective of removing the dental elements. The panoramic radiography was complemented by the Donovan's radiographic

technique; but because of the proximity of the dental element to the mandibular ramus, it was not possible to have a final fusion diagnosis. Hence, the Cone-Beam Computed Tomography—which provides precise three-dimensional information—was used to determinate the fusion diagnosis and also to help in the surgical planning. In this case report we observed that the periapical, occlusal and panoramic were not able to show details which could only be examined through the cone-beam computed tomography.

**Keywords** third molar, supernumerary tooth, oral surgery, cone-beam computed tomography

Received Jul. 5, 2009; Revision accepted Aug. 19, 2009

## Introduction

Supernumerary teeth are additional teeth in the normal series which may occur in any region of the dental arch although they are more frequent in the maxilla than in the mandible (Abrams and Nelson, 1979; Shafer *et al.*, 1993; Rajab and Hamdan, 2002; Hamasha and Al-Khateeb, 2004; Fernandes *et al.*, 2005; Harris and Clark, 2008). The teeth are considered uncommon, occurring with a frequency of 0.3% to 3.8% in the population and classified according to their position and form (Salcido-García *et al.*, 2004). According to their location they are named mesiomolars,

paramolars, parapremolars and distomolars (Rajab and Hamdan, 2002; Neville *et al.*, 2002). Concerning their form they are categorized as eumorphic, rudimentar, dysmorphic, tuberculous and conical (Liu, 1995; Rajab and Hamdan, 2002).

Fusion is the union of two developing dental germs resulting in a single large dental structure (Regezi and Sciubba, 1999). It may consist of a germ of a normal tooth with a supernumerary one or with two normal dental germs (Abrams and Nelson, 1979; Mader, 1979; Chen and Huang, 1992; Regezi and Sciubba, 1999). The pulpar chambers and canals may occur either separately or together according to the formation stage at the

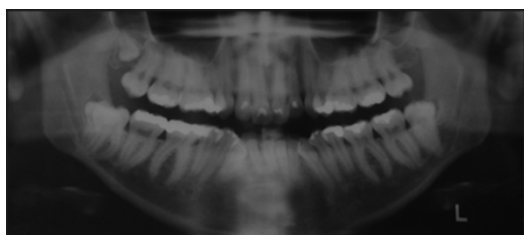
moment of the union. If this union occurs precociously, the crowns will be together with separate roots resulting in a big dental structure. If the union happens after the crown formation, the roots will probably be together (Morris, 1992).

This paper reports a clinical fusion case between a third and a fourth impacted lower molars, diagnosed through the cone-beam computed tomography (CBCT). Before the surgical procedure the patient was asked to sign the consent term, following the ethical principles in the Helsinki Declaration (2000).

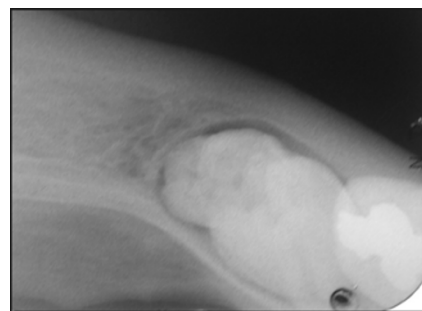
## Case report

A 26-year-old female was referred to the oral surgery clinic on Bauru Dental School (FOB/USP, Bauru, São Paulo, Brazil) when asking treatment for her third molars. During anamnesis the patient reported the use of iron sulfate for an iron deficiency anemia and the deployment of fluoxetine hydrochloride for treatment of pre-menstrual tension.

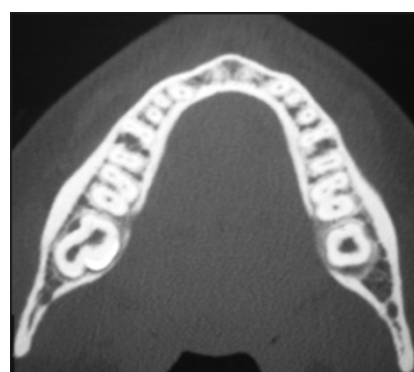
The patient was sent to a colleague physician for evaluating surgical risks; all coagulation exams were normal and she was then recommended as a precaution not to use fluoxetine hydrochloride on the day of the surgery. An intrabuccal examination revealed a tooth 48 partially erupted while the panoramic radiography showed the presence of a fourth molar (Figure 1). An occlusal radiography was taken to assess the relation between the fourth and the third molars, but it was impossible to obtain more details because the fourth molar was too close to the mandibular ramus. Donovan's technique permitted us to visualize two close crowns, however without establishing whether there was a union between them (Figure 2).



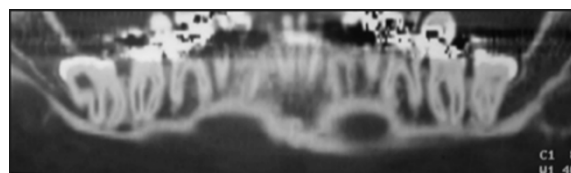
**Figure 1** Presence of the impacted third and fourth molars illustrated by the panoramic radiograph



**Figure 2** Two teeth (but not their fusion) shown by the Donovan's technique



**Figure 3** Fusion of two teeth shown by the axial CBCT



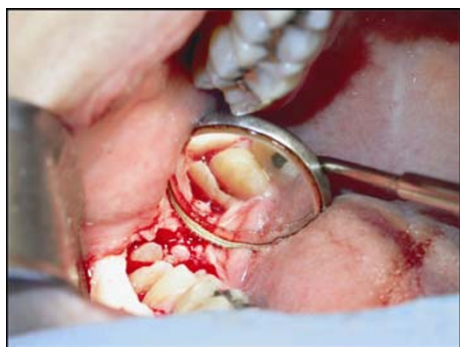**Figure 4** A close relationship between the roots and the inferior alveolar canal shown by the panoramic CBCT

A CBCT was then suggested to establish whether there was fusion, gemination, or whether the molars were two distinct teeth and also to carry out a suitable surgical planning. This exam allowed us to visualize a fusion between the teeth and a close relation of their roots with the inferior alveolar canal (Figures 3 and 4).

The patient, after being informed about the risks of the surgery, accepted them and signed the consent term. Prior to the surgery an intrabuccal and extra-buccal antiseptics was performed with 0.12% chlorhexidine gluconate (Periogard-Colgate-Brazilian Industry Palmolive, São Bernardo do Campo-SP-Brazil) and 2% chlorhexidine digluconate (F.G.M. from Brazil. Joinville-SC-Brazil),

respectively. The sterile operating field was placed. The anaesthesia was administered to the inferior alveolar, lingual and buccal nerves employing the three-position technique and adopting 4% articaine hydrochloride with 1:100,000 epinephrine (Articaine-DFL, São Paulo-SP-Brazil).

An envelope incision was performed with an oblique incision on the mesial face of the second molar, mucoperiosteum was detached, and the osteotomy was undertaken with a #6 carbide bur (Microdont, São Paulo-SP-Brazil); and the teeth were sectioned with a #4138 diamond bur (Microdont, São Paulo-SP-Brazil) by applying high rotation under cooling. The fused teeth, prior to their extraction, were separated into three fragments because of their size and the number of roots (Figure 5).



**Figure 5** Transoperative

The postoperative medication was used: amoxicillin 500 mg (Germed, São Paulo-SP-Brazil), every 8 hours by 7 days; celebra 200 mg (Pfizer, São Paulo-SP-Brazil), every 12 hours by 3 days and in case of pain dipyrone sodium 500 mg (Winthrop, São Paulo-SP-Brazil), every 4 hours.

In the fourth postoperative day the patient returned to the clinic complaining about a lower right lip paresthesia which disappeared 15 days later. She was followed during the next month and did not present any other problem.

## Discussion

The dental fusion etiology remains unknown and may originate from either genetic or environmental factors (Abrams and Nelson, 1979; Mader, 1979; Morris, 1992; von Arx, 1992; Shafer, 1993;

Regezi and Sciubba, 1999; Neville *et al.*, 2002; Hamasha and Al-Khateeb, 2004; Schneider *et al.*, 2006). However, some authors suggest that it may occur due to strength or pressure over the germs of adjacent teeth during their development which leads to a tissue necrosis as a consequence. This could make the enamel organ and the dental papillae of two teeth to produce a sole tooth (Lowell and Solomon, 1964; von Arx, 1992). This phenomenon may affect 0.5% to 1% of the population and additionally have bearing on both dentitions, especially in the region of incisors and canines (Morris, 1992; Hamasha and Al-Khateeb, 2004). In relation to the permanent dentition the prevalence of fused teeth corresponds to 0.2% and 0.05% with the deciduous dentition presenting a higher occurrence (Morris, 1992; Shafer *et al.*, 1993).

In addition, there is a difference between fusion and germination. The latter results from a failure in the division of a dental follicle, generating a big bifid crown tooth; this usually presents roots and canals in common. The fusion presents at least two ducts and two roots for the same pulpal chamber (Mader, 1979; Morris, 1992; Schneider *et al.*, 2006; Guimarães Cabral *et al.*, 2008).

Nevertheless these definitions are not enough to precisely distinguish fusion and germination, between a “normal” tooth and a supernumerary one. The final diagnosis can be obtained with both clinical and radiographic findings (Kim *et al.*, 2002).

The present clinical case is a rare example of a fusion between an impacted lower third molar and a fourth supernumerary one. According to their shape they may be classified as eumorphic (shape and size of a tooth in the normal series), rudimentary or dysmorphic (smaller and malformed), tuberculous (more than a cusp or tubercle) and conical (Grimanis *et al.*, 1991; Liu, 1995; Atwan *et al.*, 2000). The fusion—though more frequent in the premaxilla (Nazif *et al.*, 1983; Atwan *et al.*, 2000)—may occur in any region of the dental arch. The upper molars’ region is the second most common location and the patient in this case also presented a fourth upper molar on the right side.

The most common region is the incisors and canines region and the fusion of permanent posterior teeth is rare. The prevalence of fused

teeth in the permanent dentition is 0.2% (unilateral) and 0.05% (bilateral) (Morris, 1992).

Most cases of fused teeth are asymptomatic, many times discovered only through clinical or radiographic exams; nevertheless, Mader reported that the fusion might cause clinical problems related to aesthetics, the loss of space in the dental arch and periodontal problems (Mader, 1979). It is very important to identify and to enumerate the fused teeth both clinically and radiographically in order to plan a safe treatment.

Periapical, occlusal and panoramic radiographs generally provide the necessary information; however these images are not as precise as the three-dimensional ones. If the findings suggest high injury risks to the inferior alveolar nerve, exams through additional images must be included in order to observe the anatomical relation between the root and the alveolar canal (Dodson, 2005).

The CBCT permits to execute three-dimensional reconstructions providing information on axial, sagittal and coronal planes (Dodson, 2005). In addition, it clearly shows the anatomical relation of the inferior alveolar canal with the third molar, the pattern and the morphology of non-erupted or supernumerary teeth, as well as their relation to adjacent teeth and maxillary sinus (Kim *et al.*, 2002; Bayrak *et al.*, 2005). Finally it is necessary to point out that the comparison among images techniques showed that Computed Tomography produced more complete information than did the conventional radiographs. Nevertheless, the conventional equipment of computed tomography was not originally developed for dental use. Thus there are some problems such as high costs, the need of space, the long exposition time and also a high radiation level, to use this appliance in the dentistry field (Kim *et al.*, 2002; Bayrak *et al.*, 2005).

In recent years, the CBCT has innovated the concept of dentistry imaging, allowing three-dimensional reconstruction of a patient's face and skull. The new generation equipments permit the visualization of soft and hard tissues, surpassing conventional images in relation to the linear measurements of maxillaries, location and extension of dental resorptions, radicular position, presence of radicular fractures and diagnosis of bone lesions.

These equipments therefore allow a general view of the maxillomandibular complex. Besides these advantages, the CBCT utilizes a conical beam system of X-rays which exposes the patient to a single circular movement, and then to a smaller radiation level with faster acquisition of images and lower costs (Schmitt, 2006). Hence it is an important exam to provide necessary information for the surgical planning and to protect patients against unnecessary risks (Dodson, 2005).

## Conclusion

In the case reported it was observed that the traditional radiographic exams (periapical, occlusal and panoramic) were not able to show details which could only be checked through the CBCT. This case report emphasized the need to use this new diagnostic hardware in the treatment planning of the oral and maxillofacial surgery.

## References

- Abrams RA, Nelson DL (1979). Fusion of a third molar to a supernumerary tooth with an associated dentigerous cyst. *Aust Dent J*, 24(3): 141–142.
- Atwan SM, Turner D, Khalid A (2000). Early intervention to remove mesiodens and avoid orthodontic therapy. *Gen Dent*, 48(2): 166–169.
- Bayrak S, Dalci K, Sari S (2005). Case report: evaluation of supernumerary teeth with computerized tomography. *Oral Surg Oral Med Oral Pathol Oral Radiol Endod*, 100(4): E65–E69.
- Chen HS, Huang YL (1992). Fusion of third and fourth mandibular molars? *Oral Surg Oral Med Oral Pathol*, 73(6): 767.
- Dodson TB (2005). Role of computerized tomography in management of impacted mandibular third molars. *N Y State Dent J*, 71(6): 32–35.
- Fernandes AV, Rocha NS, Almeida RAC, Silva EDO, Vasconcelos BCE (2005). Impacted fourth molar: case report. *Rev Cir Traumatol Buco-Maxilo-Fac*, 5(2): 61–66.
- Grimanis GA, Kyriakides AT, Spyropoulos ND (1991). A survey on supernumerary molars. *Quintessence Int*, 22(12): 989–995.
- Guimarães Cabral LA, Firoozmand LM, Dias Almeida J (2008). Double teeth in primary dentition: report of

- two clinical cases. *Med Oral Patol Oral Cir Bucal*, 13(1): E77–E80.
- Hamasha AA, Al-Khateeb T (2004). Prevalence of fused and geminated teeth in Jordanian adults. *Quintessence Int*, 35(7): 556–559.
- Harris EF, Clark LL (2008). An epidemiological study of hyperdontia in American blacks and whites. *Angle Orthod*, 78(3): 460–465.
- Kim KD, Ruprecht A, Jeon KJ, Park CS (2002). Personal computer-based three-dimensional computed tomographic images of the teeth for evaluating supernumerary or ectopically impacted teeth. *Angle Orthod*, 73(5): 614–621.
- Liu JF (1995). Characteristics of premaxillary supernumerary teeth: a survey of 112 cases. *ASDC J Dent Child*, 62(4): 262–265.
- Lowell RJ, Solomon AL (1964). Fused teeth. *J Am Dent Assoc*, 68: 762.
- Mader CL (1979). Fusion of teeth. *J Am Dent Assoc*, 98(1): 62–64.
- Morris DO (1992). Fusion of mandibular third and supernumerary fourth molars. *Dent Update*, 19(4): 177–178.
- Nazif MM, Ruffalo RC, Zullo T (1983). Impacted supernumerary teeth: a survey of 50 cases. *J Am Dent Assoc*, 106(2): 201–204.
- Neville BW, Damm DD, Allen CM, Bouquot JE (2002). *Oral and maxillofacial pathology*. Philadelphia: Saunders.
- Rajab LD, Hamdan MA (2002). Supernumerary teeth: review of the literature and a survey of 152 cases. *Int J Paediatr Dent*, 12(4): 244–254.
- Regezi JA, Sciubba JJ (1999). *Oral pathology: clinical pathologic correlations*. Philadelphia: Saunders.
- Salcido-García JF, Ledesma-Montes C, Hernández-Flores F, Pérez D, Garcés-Ortiz M (2004). Frequency of supernumerary teeth in Mexican population. *Med Oral Patol Oral Cir Bucal*, 9(5): 403–409.
- Schmitt S (2006). Virtual diagnostics using cone beam CT. *Dent Today*, 25(6): 90–91.
- Schneider LE, Lima PVP, Grasselli S, Galvagni LE, Quoos A, Hoffmann M, et al. (2006). Radical surgical treatment of fused teeth (third and fourth molars): case report. *R Ci Méd Biol*, 5(1): 80–84.
- Shafer WG, Hine MK, Levy BM (1993). *A textbook of oral pathology*. Philadelphia: Saunders.
- von Arx T (1992). Anterior maxillary supernumerary teeth: a clinical and radiographic study. *Aust Dent J*, 37(3): 189–195.

---

\*Corresponding authors: Osny Ferreira-Junior

Address: Department of Stomatology, Dental School of Bauru, University of São Paulo, Bauru 17012-901, Brazil

Tel: 55 14 32358258 E-mail: [eduardodonto@yahoo.com.br](mailto:eduardodonto@yahoo.com.br)

Song Fan

Address: Department of Stomatology, The Second Affiliated Hospital of Sun Yat-Sen University, Guangzhou 510120, China

Tel: 86 20 81332220 E-mail: [fansong8888@163.com](mailto:fansong8888@163.com)

---