scientific reports

OPEN

Immediate four implants supported short arch rehabilitation for severe maxillary edentulism

Xiaoban Li[1,2,3], Huanze Deng[1,2,3], Ke Gu[1,2,3], Qingfu Wang[1,2]✉ & Jian Zhang[1,2]✉

To verify the feasibility of immediate short arch restorations with 4 implants in the maxillary anterior region. Patients who received immediate short arch restoration with 4 implants in the anterior region were enrolled in this retrospective study. Cone beam computed tomography (CBCT) was performed to evaluate the marginal bone loss. The incidence of prosthetic complications and patient complaints of discomfort were recorded and examined. Ten participants were enrolled in the study. Throughout the follow-up period of 13.7 ± 4.6 months, all implants used for immediate restorations in these patients demonstrated no failures. However, five patients experienced fractures of their short arch prostheses. The average marginal bone loss associated with the implants for immediate restorations was measured at 0.61 mm (95% confidence interval: 0.50 to 0.72 mm). Immediate short arch restoration with 4 implants is a potentially promising alternative in selected cases for maxillary edentulism with insufficient bone in the posterior region requiring lateral sinus floor elevation. This study presents an immediate short arch restoration using 4 implants in the maxillary anterior zone. The results indicate that immediate short arch restoration is a viable option for addressing maxillary edentulism, particularly in cases with inadequate posterior maxillary bone. However, further long-term studies are required to confirm its efficacy and stability over time.

Full-arch implant-supported fixed restoration is an attractive treatment option due to the ability to provide immediate restorations, thereby reducing the duration of edentulism[1]. In 1998, Paulo Maló first proposed the all-on-4 treatment concept to support a full-arch restoration[2]. Numerous studies strongly support using 4 implants in the mandible and 6 in the maxilla for full-arch immediate restoration[3–5]. A minimum of 30 N-centimeters (Ncm) of initial stability is typically recommended for each implant in immediate full-arch restorations. Posterior cantilevers are generally not recommended in fixed prostheses because chewing forces can damage the implants and prostheses[6–8]. Immediate full-arch restorations in the maxilla pose challenges due to factors such as the proximity of the maxillary sinus, significant atrophy, and softening of the alveolar bone. Currently, there is no consensus regarding the use of four maxillary implants for immediate restoration, as the poorer bone quality in the maxilla compared to the mandible hampers the ability to achieve sufficient initial stability.

Zygomatic implants have been utilized to treat severely atrophic maxillas. While the success rate of zygomatic implants is impressive, the complexity of the procedure and the potential for serious complications restrict their widespread use.

[9,10]. Pterygoid implants can eliminate the posterior cantilevers of the prostheses; however, the surgical procedure is challenging due to limited access and visibility in the pterygoid region, and patient hygiene is more difficult to maintain[11,12]. Simultaneous or staged placement of implants during lateral sinus floor elevation (LSFE) is often used to address insufficient bone in the posterior maxilla[13]. In such cases, immediate restoration with implants placed simultaneously during sinus floor elevation is infeasible due to inadequate initial stability. A clinical decision should consider 3 fundamental elements: the current health status of the patient, the objective and preference of the patient, and the scientific evidence on the safety and efficacy of the surgical technique[14]. Generally, patients choose minimally invasive, quicker, and cost-effective approaches.

In the present study, we propose the immediate restoration of the short arch using 4 implants in the maxillary anterior region. This approach aims to enhance patients' aesthetics and partial chewing function while allowing adequate healing time for both the bone grafting material and the implants in the maxillary sinus. Compared to zygomatic and pterygoid implants, implants placed after LSFE provide superior biomechanical advantages, create

[1]Department of Oral Implantology, Tianjin Stomatological Hospital, School of Medicine, Nankai University, No. 75 Dagubei Road, Heping District, Tianjin 300041, China. [2]Tianjin Key Laboratory of Oral and Maxillofacial Function Reconstruction, Tianjin 300041, China. [3]Xiaoban Li, Huanze Deng and Ke Gu contributed equally to this work. ✉email: wqfjwd@163.com; zhangstoma@hotmail.com

a better-contoured prosthesis, and are easier to maintain. By utilizing immediate restoration with 4 implants in the anterior region, we can effectively preserve the patient's essential aesthetics and masticatory function.

Materials and methods

This is a retrospective study. Patients with maxillary edentulism and insufficient posterior bone volume receiving an immediate short arch restoration with 4 implants in the anterior region from July 2020 to December 2022 were enrolled. The inclusion criteria were as follows: (a) preoperative crosssectional CBCT images show sinus floor defects, (b) the anterior region had sufficient bone volume for the placement of 4 implants with adequate initial stability. (c) completed LSFE followed by dental implant placement, (d) well-documented medical charts reporting details regarding prosthetic complications. The exclusion criteria were as follows: (a) incomplete or low-quality clinical and radiographic documentation, (b) refusal to undergo the LSFE procedure; (c) untreated periapical disease or periodontal disease; (d) acute and chronic inflammation in the maxillary sinus; (e) uncontrolled diabetes and other systemic conditions; (f) pregnancy or lactation; (g) severe alcoholism/drug abuse; (h) smokers; (i) Type IV bone quality (Lekholm and Zarb classification). All patients provided informed consent before inclusion into the study. All surgeries were conducted at the Department of Oral Implantology, Tianjin Stomatological Hospital. The study protocol adhered to the tenets of the 2008 Helsinki Declaration and was approved by the Ethics Committee of Tianjin Stomatological Hospital (approval number: PH2023-B-017).

An alginate impression was taken to create a diagnostic model that captured the patient's centric occlusion relationship using a wax bite. A diagnostic denture was then fabricated, featuring randomly distributed radiopaque points across its surface (Fig. 1a). Following this, a cone beam computed tomography (CBCT) scan was conducted (Fig. 1b). Separate digital scans of both the patient's diagnostic model and the denture were obtained. The digital scan data were integrated with the CBCT data using CoDiagnostiX Version 9.11 software (Straumann, Switzerland) to generate a comprehensive digital model encompassing the bone structure, soft tissues, and virtual prosthesis.

To facilitate prosthetically guided implant placement, implants were accurately designed, and digital guides were created (Fig. 1c). Two implants were planned for zones 1, 2, and 3. Additionally, an immediate short arch restoration with four implants was designed for zones 1 and 2, as there was insufficient bone volume in zone 3 to achieve initial stability during implant placement[15].

The accuracy and reliability of the digital guides were verified through O-Bite (DMG, Germany), and the Template Fixation Pin (Institut Straumann AG, Switzerland) were inserted under local anesthesia (Fig. 2a, b). Implant cavities were prepared using a 2 mm pilot drill following the digital guide in the maxillary anterior region. After the removal of a digital guide, an incision was made along the alveolar ridge to expose the alveolar bone and the lateral wall of the maxillary sinus. Implant cavities were prepared by gradually transitioning to larger diameter drills, followed by the insertion of the implants (Fig. 2c). The implants used in this study were Straumann BLT (Straumann, Switzerland) and Nobel Active (Nobel Biocare, Sweden), both achieving initial stability exceeding 30 Ncm. Screw-retained abutments and healing caps were then installed, and bone augmentation was carried out at sites where the buccal bone plate was deficient. The LSFE procedure was performed in zone 3, beginning with the creation of a bone window using ultrasonic instruments. Subsequently, the maxillary sinus membrane was elevated, and Bio-Oss (Geistlich, Switzerland) was inserted (Fig. 2d, e). Simultaneous or delayed (8 months later) implant placement was performed, followed by tension-free wound closure (Fig. 2f). Postoperative CBCT was conducted to assess the bone level around the implants.

An immediate impression was obtained using a stabilization splint, and the occlusal relationship following surgery was recorded (Fig. 3a). Subsequently, computer-aided design/computer-aided manufacturing (CAD/CAM) resin prostheses were fabricated (Fig. 3b). The prosthetic length was determined based on the distal implant location to prevent cantilever and restore 6 to 8 teeth. The immediate restoration was completed within one week postoperatively (Fig. 3c). To ensure proper placement of the prosthesis, panoramic imaging was performed (Fig. 4). Patients were advised to consume soft foods and utilize an irrigator and interproximal brushes to maintain oral hygiene.

During the second stage of surgery, the screw-retained abutments were replaced after the implants in zone 3 achieved osseointegration. The immediate short arch restoration was removed, and scan bodies were connected to the implants to capture the soft tissue contours using TRIOS 4 (3Shape A/S, Denmark) (Fig. 5a, b). The scan bodies were then replaced and scanned with ICam4D (Imetric4D Imaging Sàrl, Switzerland) to determine the three-dimensional positions of the implants (Fig. 5c, d). A digital model capturing the occlusal relationship was created by intraoral scanning the immediate prosthesis with the oral scanner. Digital models of the soft tissue

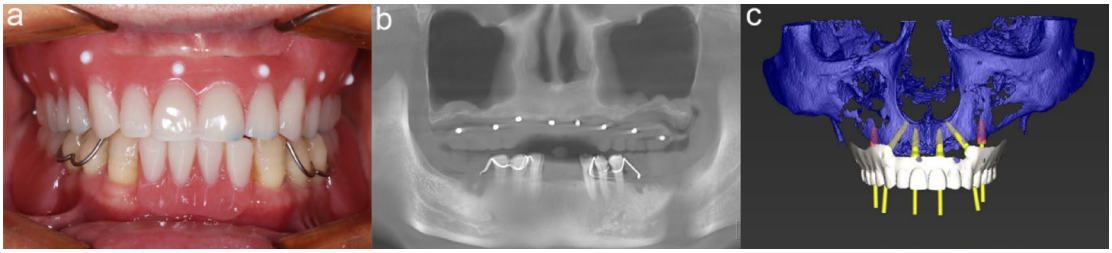

Fig. 1. Preoperative design. (**a**) diagnostic denture (**b**) Preoperative cone beam computed tomography (CBCT) scan (**c**) Prosthetically guided implant design.

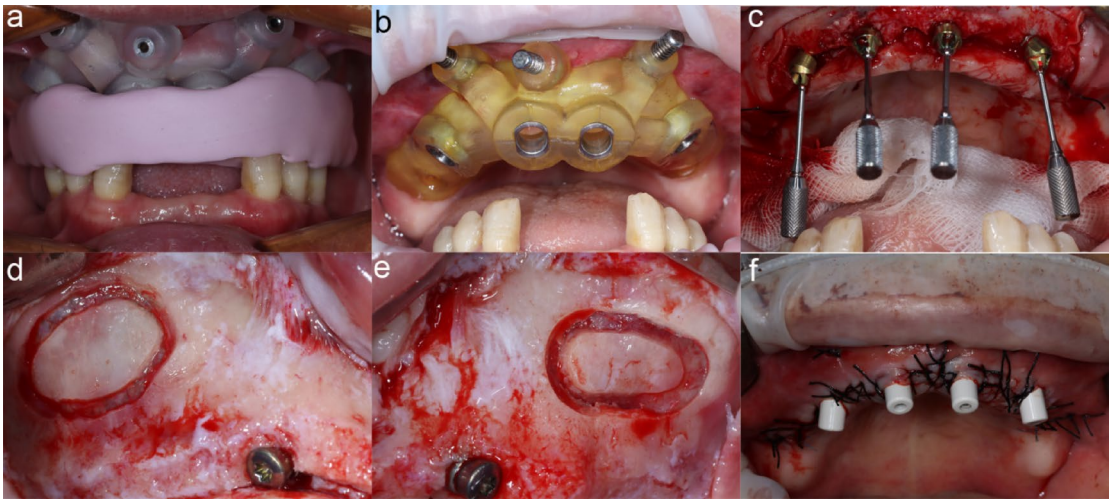

Fig. 2. Surgical procedure. (**a**) Verification of guide accuracy. (**b**) Fixation of guide. (**c**) Implants placement. (**d**, **e**) Window openings in the lateral wall of the maxillary sinus. (**f**) tension-free wound closure.

Fig. 3. Immediate restoration. a, Impression with splint. b, Immediate prosthesis. c, Completion of immediate restoration.

contours, implant positions, and occlusal relationships were aligned, leading to the design and fabrication of the final prostheses, which were completed and placed (Fig. 5e). Panoramic imaging was again performed to verify the proper positioning of the prosthesis (Fig. 5f). Finally, a postoperative CBCT was conducted to evaluate the bone levels surrounding the implants.

The occurrence of prosthetic complications and patient complaints of discomfort were recorded, and marginal bone loss of the implants used for immediate restoration was measured. Marginal bone loss was defined as the difference in proximal and distal mesial bone height of each implant, measured immediately post-operation and at the time of final restoration. To ensure objectivity, all measurements were performed independently by XB. L and HZ. D. Inter-rater reliability was assessed using Cohen's kappa statistic, which showed almost perfect agreement ($\kappa = 0.87$).

Statistical analysis was performed using SPSS software (IBM SPSS Statistics, v21.0; IBM Corp). For continuous variables (e.g., bone loss): Data normality was assessed using the Shapiro-Wilk test. Normally distributed data are presented as standard descriptive statistics (mean, standard deviation, minimum, maximum, and 95% CI). Non-normal data are reported as median (IQR) and analyzed with Wilcoxon signed-rank tests (paired) or Mann-Whitney U tests (unpaired).

Results

Ten patients participated in the study, consisting of 7 females and 3 males, with ages ranging from 39 to 66 years. Among them, 7 patients retained their mandibular teeth, while 3 received implant-supported full arch restorations. The short arches were restored to the bilateral cuspids in 4 patients and to the bilateral first premolars in 6 patients. The duration for replacing temporary short-arch prostheses varied from 8 to 21 months, with a mean of 13.7 ± 4.6 months. Notably, none of the 40 implants used for immediate restorations in any of the patients failed.

In terms of prosthetic complications, five patients experienced fractures of the short-arch prostheses between 5 and 16 months following immediate restoration (see Table 1). All fractures occurred specifically within the distal cantilever region of the interim CAD/CAM resin prostheses, primarily at the connector or pontic areas. It is important to highlight that these interim prostheses were monolithic resin restorations without metal framework reinforcement. Further analysis revealed no direct correlation between prosthesis fractures and

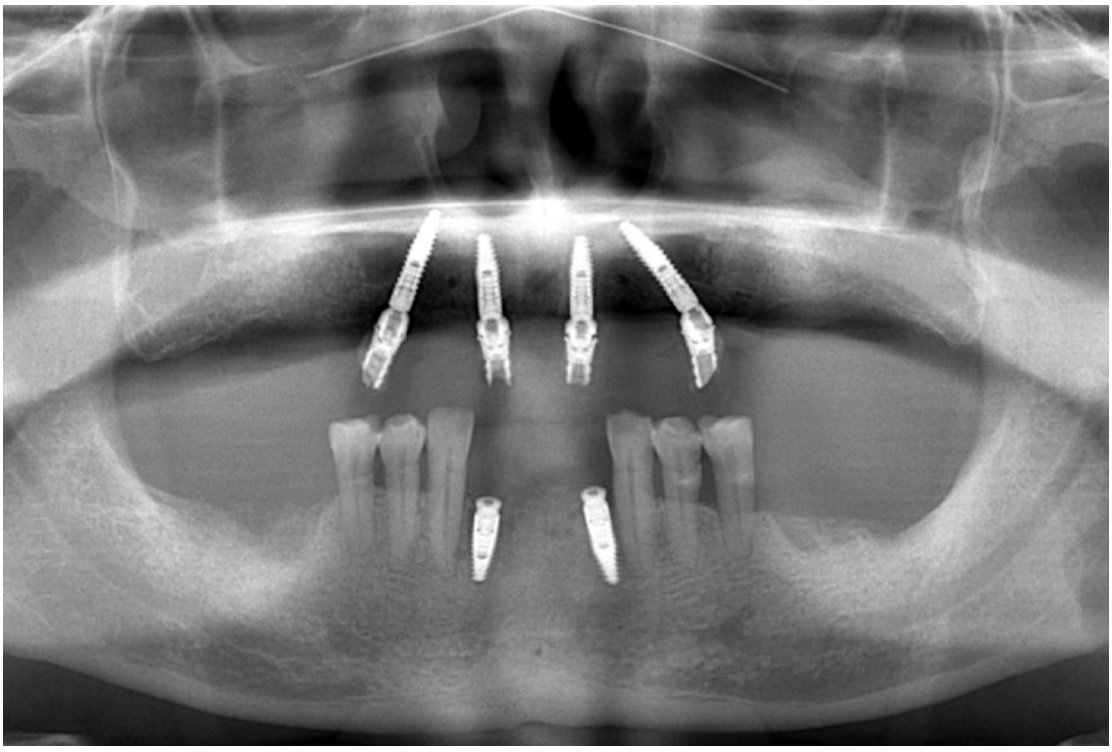

Fig. 4. Panoramic imaging of immediate restoration.

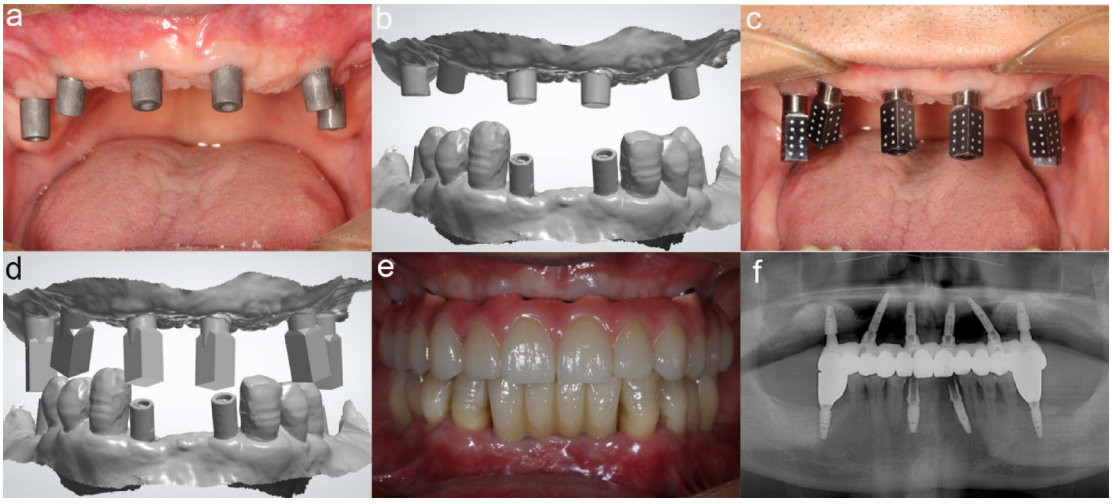

Fig. 5. Final restoration. (**a**, **b**) Intraoral scanning for soft tissue contour. (**c**, **d**) Intraoral scanning for the position of implants. (**e**) Picture of final restoration in mouth. (**f**) Panoramic imaging of final restoration.

specific implant positions; instead, the failures appeared to be more closely related to the cantilever design, the mechanical limitations of the resin material, and individual variations in occlusal loading.

Meanwhile, 2, 3, and 2 patients complained of impacted articulation, cheek/lip biting, and poor mastication, respectively. The average marginal bone loss of implants for immediate restorations was 0.61 mm (95% CI 0.50 to 0.72 mm) (Table 2).

Discussion

The findings of this study demonstrate the feasibility of immediate short arch restoration using four implants in cases of maxillary edentulism. This is supported by the absence of implant failure, minimal marginal bone loss, and manageable prosthetic complications.

Sex	Age (years)	Prosthetic complication times	Timing of prosthetic complications	Mandible	Restored Teeth	Replacement Period (months)
M	60	None	None	Teeth	8	16
M	42	1	5	Implant-supported fixed prosthesis	6	8
F	39	None	None	Teeth	6	20
F	49	None	None	Teeth	8	16
F	60	1	16	Teeth	8	21
F	63	1	6	Teeth	8	8
M	55	1	6	Implant-supported fixed prosthesis	6	13
F	49	2	5;8	Implant-supported fixed prosthesis	8	12
F	66	None	None	Teeth	6	9
F	65	None	None	Teeth	8	14

Table 1. Demographic and surgical data of participants.

	Mean	Standard deviation	Maximum	Minimum	Median	Lower 95% CI	Upper 95%CI
Marginal Bone Loss (mm)	0.61	0.34	1.44	0.03	0.62	0.50	0.72

Table 2. Marginal bone loss of implants. CI, confidence interval.

Immediate prosthetic restoration achieves more midfacial soft tissue levels and bone volume maintenance compared to delayed prosthetic restoration[16]. Immediate fixed bridge restorations with implants are significantly more complicated in the edentulous maxilla than in the mandible. The bone density of the maxilla is usually lower than that of the mandible, which complicates the achievement of adequate initial stability during implant placement[17]. Achieving adequate initial stability with zygomatic implants is a highly technical process. Lateral sinus floor elevation (LSFE) is a conventional method used to address insufficient bone height in the posterior region, known for its reduced complexity and proven reliability. However, one of its drawbacks is the lengthy treatment duration, which can be challenging for edentulous patients.

In this case, an edentulous maxilla with insufficient bone height in the posterior region required LSFE. To facilitate an immediate short arch restoration, four implants were placed in the anterior region. This approach made use of the bone located between the bilateral maxillary sinuses to ensure initial stability. An immediate restoration was performed, providing both aesthetic benefits and functional masticatory capability while the patient awaited osseointegration of the implants in the maxillary sinus. The implant survival rate for short arch immediate restorations was 100%, with no significant complications, demonstrating that this method is a viable option.

Micromotion of the implant-bone interface during healing should be controlled to within 150 μm to achieve osseointegration[18]. Linking implants to an immediate restoration helps distribute stress and keeps the micromotion of each implant within acceptable limits. Clinical studies indicate that immediate restoration with splinted connections is effective when the initial stability exceeds 30 Ncm. The marginal bone loss observed in immediately loaded implants is similar to that in conventionally healed implants, with most loss occurring within the first 3 to 4 months post-placement. If stresses cause micromotion to exceed acceptable limits during the osseointegration process, significant marginal bone loss or even osseointegration failure may occur. While immediate restoration of a short arch that only restores the anterior region can lead to implant complications due to large lateral forces, the present study found no such complications.

Additionally, no implant failure was found, and the average marginal bone loss of implants for immediate restorations was 0.61 ± 0.34 mm at an average follow-up of 13.4 ± 4.5 months. The criterion for implant success is defined as marginal bone resorption controlled within 1.5 mm in the first year and less than 0.2 mm per year thereafter[19]. This positive outcome can be attributed to effective occlusal force management and a high level of patient compliance. However, the main complication associated with immediate restorations was the fracture of the temporary prosthesis, likely due to the limited strength of resin prostheses and insufficient support from the premolar. It is clear that not all patients are able to manage their occlusal forces within the tolerances required for short arch restorations.

In typical centric occlusion, the posterior teeth make uniform contact to maintain the vertical dimension under masticatory forces. However, during forward and lateral movements, the guidance provided by the anterior teeth causes the posterior teeth to disengage. The immediate short arch restoration in this study involved only 6 to 8 teeth, which was insufficient for adequate posterior support and necessitated continuous control of occlusal forces. Fractures of the restorations occurred 5 to 16 months after the immediate restoration, during which time the implants osseointegrated without any implant failures or significant marginal bone loss.

Prosthetic fractures are associated with material stress fatigue and excessive occlusal forces. In clinical practice, the risk of these fractures can be minimized by using reinforcing metal brackets in temporary prostheses, controlling occlusal forces, and preventing parafunctional movements. If restorations become fractured, they can either be bonded with a self-adhesive resin or refabricated as needed.

Prosthetic complications were noted in all three patients who received implant-supported full-arch restorations in their mandibles, compared to only two out of seven patients with natural teeth in their mandibles

(Table 2). The lack of physiologic mobility in implants subjected the short arch restorations to greater occlusal forces, underscoring the need to reduce these forces in affected patients. The anticipated duration to achieve the final restoration was approximately 8 months for patients undergoing LSFE with simultaneous implant placement and about 12 months for those receiving staged implant placement. However, delays in follow-up appointments due to COVID-19 extended the overall treatment duration. Timely follow-up and effective management of occlusal forces may help reduce prosthetic complications.

Compared to implant failure and unacceptable marginal bone resorption, prosthetic complications (prosthesis fracture) appear to be more acceptable. Zygomatic implants are sometimes used in cases of insufficient bone volume in the maxillary posterior region, but their failure rate (24.24%) and complication incidence (53.73%) are significantly higher than those of implants placed after LSFE[20]. The common complications of zygomatic implants include peri-implantitis[21] and maxillary sinus mucosal thickening[22], which are more difficult to manage than prosthetic fractures. Although immediate short arch restoration, covering only 6 to 8 teeth, led to some complaints related to articulation, cheek bite, and poor mastication, most patients were satisfied with the treatment. Alternative strategies for immediate full-arch rehabilitation in severely atrophic jaws have been proposed, including nerve relocation with immediate restoration[23] and the use of custom-made subperiosteal titanium implants[24]. Other less invasive techniques, such as a modified transalveolar two-step osteotome-mediated approach, have been reported with favorable mid-term outcomes[25]. Compared with other techniques, the LSFE protocol selected for this study was tailored to the specific bone defect dimensions and anatomical conditions of each patient. This approach aimed to ensure predictable grafting and facilitate immediate restoration.

When interpreting the results, it is important to consider the limitations of this research. The study was a small-sample, retrospective analysis without a control group, which limits statistical power and prevents definitive conclusions regarding the performance of this protocol in comparison to alternative methods. Although the mean follow-up period of approximately 14 months is adequate for evaluating short-term feasibility and safety, it is insufficient for assessing long-term outcomes. Therefore, the findings should be viewed as preliminary. Future studies with larger samples, multicenter involvement, prospective designs, and extended follow-up are needed to validate the long-term efficacy and stability of this approach.

Conclusion

In summary, the findings of this preliminary study indicate the potential feasibility of immediate short arch restoration using 4 implants as a treatment alternative for selected patients with maxillary edentulism and posterior bone deficiency requiring LSFE. The observed marginal bone loss was acceptable, and complications were manageable within the short follow-up period. However, these results are limited by the study's retrospective design, small sample size, and lack of a control group. Consequently, while the protocol appears viable, larger prospective studies with comparative groups and long-term follow-up are essential to confirm its clinical efficacy and mechanical stability.

Data availability

All data generated or analysed during this study are included in this published article.

Received: 28 April 2025; Accepted: 13 January 2026
Published online: 19 January 2026

References

1. Srinivasan, M., Kamnoedboon, P., Angst, L. & Müller, F. Oral function in completely edentulous patients rehabilitated with implant-supported dental prostheses: A systematic review and meta-analysis. *Clin. Oral. Implants. Res.* **34**, 196–239 (2023).
2. Maló, P., Rangert, B. & Nobre, M. All-on-4 immediate-function concept with Brånemark system implants for completely edentulous maxillae: a 1-year retrospective clinical study. *Clin. Implant Dent. Relat. Res.* **7**, S88–S94 (2005).
3. Zhang, Y. et al. Comparison of 4- or 6-implant supported immediate full-arch fixed prostheses: A retrospective cohort study of 217 patients followed up for 3–13 years. *Clin. Implant Dent. Relat. Res.* **25**, 381–397 (2023).
4. Chen, W. et al. A retrospective study on patient satisfaction and oral Health-Related quality of life with fixed 4- or 6-implant supported prostheses over 3–7 years. *Clin. Implant Dent. Relat. Res.* **27**, e13394 (2025).
5. Maló, P., de Araújo Nobre, M., Lopes, A., Ferro, A. & Botto, J. The All-on-4 treatment concept for the rehabilitation of the completely edentulous mandible: A longitudinal study with 10 to 18 years of follow-up. *Clin. Implant Dent. Relat. Res.* **21**, 565–577 (2019).
6. Papaspyridakos, P., Chen, C. J., Chuang, S. K. & Weber, H. P. Implant loading protocols for edentulous patients with fixed prostheses: a systematic review and meta-analysis. *Int. J. Oral Maxillofac. Implants.* **29**, 256–270 (2014).
7. Maló, P., Lopes, A., de Araújo Nobre, M. & Ferro, A. Immediate function dental implants inserted with less than 30 N·cm of torque in full-arch maxillary rehabilitations using the All-on-4 concept: retrospective study. *Int. J. Oral Maxillofac. Surg.* **47**, 1079–1085 (2018).
8. Agliardi, E. L., Pozzi, A., Romeo, D. & Del Fabbro, M. Clinical outcomes of full-arch immediate fixed prostheses supported by two axial and two Tilted implants: A retrospective cohort study with 12–15 years of follow-up. *Clin. Oral. Implants. Res.* **34**, 351–366 (2023).
9. Al-Nawas, B. et al. ITI consensus report on zygomatic implants: indications, evaluation of surgical techniques and long-term treatment outcomes. *Int. J. Implant Dentistry*. **9**, 28 (2023).
10. Menchini-Fabris, G. B. et al. Immediate Full-Arch restorations supported by conventional implants plus Uni- or bilateral zygomatic implants: A three to five years retrospective radiologic and clinical comparison. *Int. J. Periodontics Restor. Dent.* **0**, 1–29 (2025).
11. Aalam, A. A., Krivitsky-Aalam, A., Kurtzman, G. M. & Mahesh, L. The severely atrophic maxilla: decision making with zygomatic and pterygoid dental implants. *J. Oral Biology Craniofac. Res.* **13**, 202–206 (2023).
12. Signorini, L., Faustini, F., Samarani, R. & Grandi, T. Immediate fixed rehabilitation supported by pterygoid implants for participants with severe maxillary atrophy: 1-Year postloading results from a prospective cohort study. *J. Prosthet. Dent.* **126**, 67–75 (2021).
13. Testori, T., Weinstein, T., Taschieri, S. & S Wallace, S. Risk factors in lateral window sinus elevation surgery. *Periodontology 2000*. **81**, 91–123 (2019).

14. Elwyn, G., Cochran, N. & Pignone, M. Shared decision Making-The importance of diagnosing preferences. *JAMA Intern. Med.* **177**, 1239–1240 (2017).
15. Bedrossian, E., Sullivan, R. M., Fortin, Y., Malo, P. & Indresano, T. Fixed-prosthetic implant restoration of the edentulous maxilla: a systematic pretreatment evaluation method. *J. Oral Maxillofacial Surgery: Official J. Am. Association Oral Maxillofacial Surg.* **66**, 112–122 (2008).
16. Crespi, R. et al. Tissue remodeling in immediate versus delayed prosthetic restoration in fresh socket implants in the esthetic zone: Four-year follow-up. *Int. J. Periodontics Restor. Dent.* **38**(Suppl), s97–s103 (2018).
17. Chrcanovic, B. R., Albrektsson, T. & Wennerberg, A. Reasons for failures of oral implants. *J. Rehabil.* **41**, 443–476 (2014).
18. Szmukler-Moncler, S., Salama, H., Reingewirtz, Y. & Dubruille, J. H. Timing of loading and effect of micromotion on bone-dental implant interface: review of experimental literature. *J. Biomed. Mater. Res.* **43**, 192–203 (1998).
19. Albrektsson, T., Zarb, G., Worthington, P. & Eriksson, A. R. The long-term efficacy of currently used dental implants: a review and proposed criteria of success. *Int. J. Oral Maxillofac. Implants.* **1**, 11–25 (1986).
20. Di Cosola, M. et al. Retrospective analysis of clinical and radiologic data regarding zygomatic implant rehabilitation with a Long-Term Follow-Up. *Int. J. Environ. Res. Public Health*. **18**, 12963 (2021).
21. Vrielinck, L. et al. Peri-zygomatic infection associated with zygomatic implants: A retrospective longitudinal cohort study. *Clin. Oral. Implants. Res.* **33**, 405–412 (2022).
22. Zhao, K. et al. Long-term Schneiderian membrane thickness changes following zygomatic implant placement: A retrospective radiographic analysis using cone beam computed tomography. *Clin. Oral. Implants. Res.* **29**, 679–687 (2018).
23. Vinci, R., Cosola, S., Borsi, A., Speroni, S. & Esposito, M. Immediate loading after implant placement with relocation of the inferior alveolar nerve in atrophic mandibles: A 1-Year retrospective case series. *Clin. Trials Dentistry*. **6**, 37–48 (2024).
24. Vatteroni, E. et al. A retrospective radiological and clinical survey of Full-Arch immediate fixed prostheses supported by Custom-Made Three- dimensional printed subperiosteal titanium implants in patients with severe atrophic jaws: implant success code. *Int. J. Oral Maxillofac. Implants*. **0**, 1–27 (2025).
25. Crespi, R., Toti, P., Covani, U., Crespi, G. & Menchini-Fabris, G. B. Clinical and radiographic evaluation of modified transalveolar Two-Step Osteotome-Mediated localized maxillary sinus elevation: A retrospective computed tomography study with a 3-Year Follow-up. *Int. J. Oral Maxillofac. Implants*. **36**, 553–560 (2021).

Author contributions

X.L.: Conceptualization, Data curation, Writing—original draft, Writing—Reviewing and Editing; H.D.: Data curation, Methodology, Validation, Writing-original draft, Writing—Reviewing and Editing; K.G.: Data curation, Methodology, Validation; Q.W.: Designing the experimental protocol, Writing—Reviewing and Editing, Methodology, Critical revision of the manuscript; J.Z.: Conceptualization, Supervision, Writing—Reviewing and Editing, Project administration, Funding acquisition.

Funding

This study was supported by Tianjin Key Medical Discipline (Specialty) Construction Project (TJYX-ZDXK-048 A), Tianjin Health Research Project (TJWJ2024XK018).

Declarations

Competing interests

The authors declare no competing interests.

Ethical approval

The study was approved by the Ethics Committee of Tianjin Stomatological Hospital (approval number: PH2023-B-017).

Informed consent

The written consent was obtained from study participants.

Additional information

Correspondence and requests for materials should be addressed to Q.W. or J.Z.

Reprints and permissions information is available at www.nature.com/reprints.

Publisher's note Springer Nature remains neutral with regard to jurisdictional claims in published maps and institutional affiliations.

Open Access This article is licensed under a Creative Commons Attribution-NonCommercial-NoDerivatives 4.0 International License, which permits any non-commercial use, sharing, distribution and reproduction in any medium or format, as long as you give appropriate credit to the original author(s) and the source, provide a link to the Creative Commons licence, and indicate if you modified the licensed material. You do not have permission under this licence to share adapted material derived from this article or parts of it. The images or other third party material in this article are included in the article's Creative Commons licence, unless indicated otherwise in a credit line to the material. If material is not included in the article's Creative Commons licence and your intended use is not permitted by statutory regulation or exceeds the permitted use, you will need to obtain permission directly from the copyright holder. To view a copy of this licence, visit http://creativecommons.org/licenses/by-nc-nd/4.0/.

© The Author(s) 2026